



Aortobifemoral reconstruction and renal transplantation in a patient with abdominal aortic aneurysm and occlusion of iliac arteries: A case report

Aortobifemoralna rekonstrukcija i transplantacija bubrega kod bolesnika sa aneurizmom abdominalne aorte i okluzijom ilijačnih arterija

Aleksandar Tomić*[†], Novak Milović^{†‡}, Ivan Marjanović*[†], Ivan Leković*^{*},
Zoran Bjelanović*, Momir Šarac*, Neven Vavić[§], Ljiljana Ignjatović[§],
Dušica Stamenković^{¶||}, Saša Micković*

*Clinic for Vascular and Endovascular Surgery; [‡]Clinic for Urology, [§]Clinic for Nephrology, ^{||}Clinic for Anesthesia and Intensive Care, Military Medical Academy, Belgrade, Serbia; [†]Faculty of Medicine of the Military Medical Academy, University of Defence, Belgrade, Serbia

Abstract

Introduction. Aortoiliac occlusive disease and abdominal aortic aneurysm in patients with renal insufficiency on hemodialysis can significantly influence the success of renal transplantation. In the recent past, advanced atherosclerosis was considered as contraindication for renal transplantation. Complicated creation of vascular anastomoses and progression of occlusive or aneurysmal disease were the main reasons. **Case report.** We presented a 52-year-old man with a 5-year history of end-stage renal disease on haemodialysis. The patient was previously excluded from renal transplantation program because of severe aortoiliac atherosclerosis and abdominal aortic aneurysm. Resection of abdominal aortic aneurysm with occlusion of the iliac arteries and reconstruction with aortobifemoral synthetic grafts was performed and followed by cadaveric renal transplantation. **Conclusion.** Advanced atherosclerotic disease in aortoiliac segment requires elective vascular surgical reconstruction, as part of preparation for renal transplantation in patients with end-stage renal disease.

Key words:

atherosclerosis; iliac artery; aortic aneurysm, abdominal; renal dialysis; comorbidity; vascular surgical procedures; kidney transplantation.

Apstrakt

Uvod. Okluzivna aortoilijačna bolest i aneurizma abdominalne aorte kod bubrežnih bolesnika na hemodijalizi mogu značajno uticati na uspešnost transplantacije bubrega. Ne tako davno, uznapređovala ateroskleroza bila je kontraindikacija za transplantaciju bubrega, jer značajno otežava kreiranje vaskularne anastomoze, a okluzivna, odnosno aneurizmatička bolest nastavlja tok. **Prikaz bolesnika.** Bolesnik, star 52 godine, sa petogodišnjom istorijom terminalne bubrežne bolesti na hemodijalizi, bio je prethodno odbijen za transplantaciju bubrega zbog teške aortoilijačne ateroskleroze i aneurizme abdominalne aorte. To je prvi slučaj vaskularne resekcije aneurizme abdominalne aorte udružene sa aortoilijačnom okluzivnom bolešću u našoj zemlji i rekonstrukcije sa aortobifemoralnim sintetskim graftom koja je prethodila kadaveričnoj transplantaciji bubrega. **Zaključak.** Uznapređovala aterosklerotska bolest aortoilijačnog segmenta zahteva elektivnu vaskularnu hirušku rekonstrukciju koja bi trebalo da prethodi transplantaciji bubrega kod bolesnika sa terminalnom bubrežnom insuficijencijom.

Ključne reči:

ateroskleroza; a. iliaca; aorta, abdominalna, aneurizma; hemodijaliza; komorbiditet; hirurgija, vaskularna, procedure; transplantacija bubrega.

Introduction

Coexistence of atherosclerosis in aortoiliac segment and renal insufficiency is not rare and arterial occlusion and stenosis can complicate renal transplantation. In the past, aneu-

rismal lesions localized in aortoiliac segment and the use of synthetic grafts were contraindicated in transplant surgery. In recent years, large number of patients on haemodialysis (HD) and treatment cost, urged for change of inclusion criteria for renal transplantation including the presence of aortoi-

iliac aneurysms and occlusive disease. In the past few years, there were few articles on the successful kidney transplant after aortoiliac reconstruction¹⁻³.

Case report

A male 52-years-old patient (85 kg, 185 cm), with end-stage renal disease (ESRD), five years on HD (three times a week), with no diuresis and the serum creatinine level of 1,163 mmol/L, was rejected for renal transplantation due to the presence of severe aortoiliac atherosclerosis. Abdominal aortic aneurysm (AAA) 4.5 cm in diameter with occlusion of both iliac arteries was verified on multislice computed tomography (MSCT) (Figure 1). The patient had symptoms of intermittent claudications in legs at the walking distance of 100 m.

Resection of AAA and aortobifemoral reconstruction with Dacron bifurcated prosthesis was performed (Figure 2). The uneventful postoperative period with symptoms withdrawal was followed by pretransplant reexamination. Abdominal ultrasonography and intravenous urography were normal.

Three months later, cadaveric renal transplantation was performed. A donor was A positive, HLA compatibility 3/6 and negative "cross-match" using complement dependant cytotoxicity (CDC) were recorded. The procedure was performed through the right Gibson incision. The left kidney procured from cadaveric donor was inserted in the right iliac fosse. The renal artery was anastomosed with the right branch of bifurcated graft in "end-to-side" fashion with continuous 6/0 polypropilene (Figure 3). Unfortunately, the renal vein was transected during procurement and reconstruction was done with a cadaveric caval vein (Figure 4). Disproportion between the caval vein and the origin of renal vein was solved with caval vein preparation using spiral sewing and lumen reduction. One end of the new vein conduit was connected with the origin of renal vein on the kidney in "end-to-end" fashion anastomosis. The opposite end of the vein conduit was connected with the iliac vein in "end-to-side" fashion anastomosis (Figure 5). Antireflux ureterocystoneostomias (UCN) with J-J stent were made.

Diuresis started after 24 h with ultrasound color Doppler exam verification of good perfusion of transplanted kidney and good flow through arterial and venous anastomo-

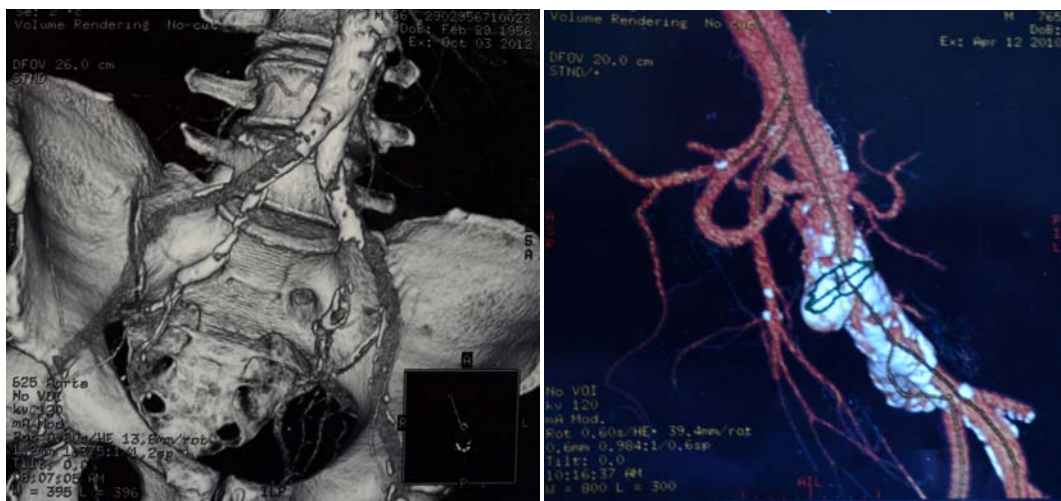


Fig. 1 – Multislice computed tomography (MSCT) angiography preoperatively.

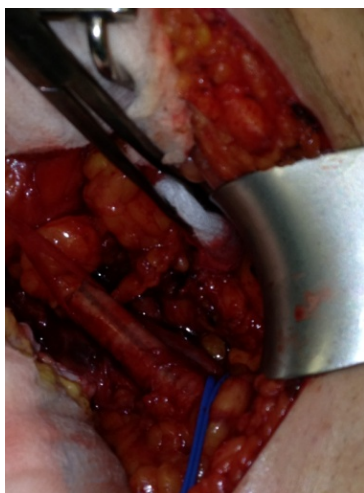

Fig. 2 – Previous reconstruction with a Dacron bifurcated prosthesis.

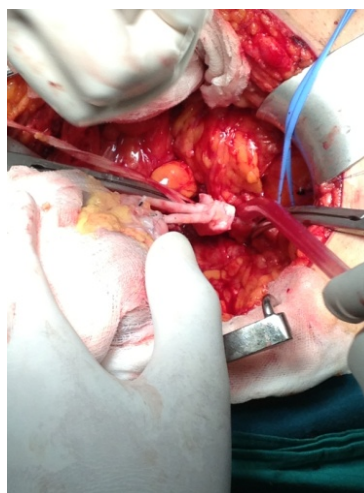

Fig. 3 – Renal artery anastomosed with the right branch of bifurcated graft in the "end-to-side" fashion with continuous 6/0 polypropilene.

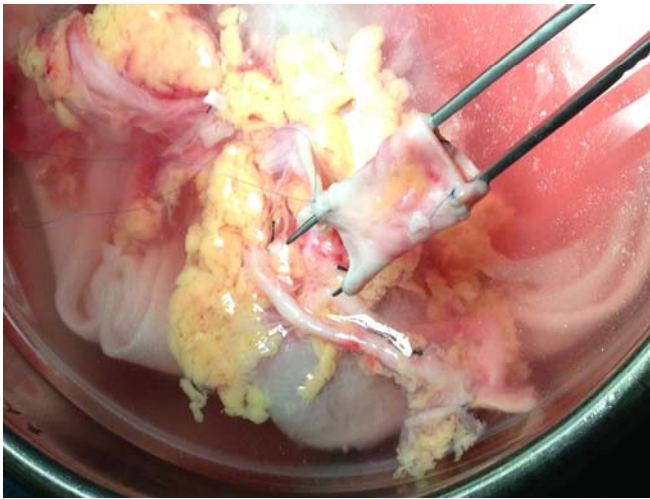


Fig. 4 – Reconstruction with a cadaveric caval vein.

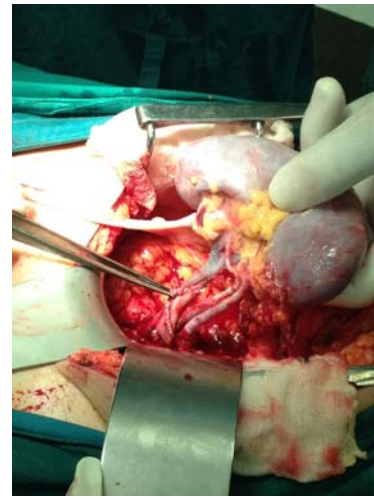

Fig. 5 – Final picture – spiral sewing and lumen reduction.

sis. On the second postoperative day diuresis was 11 L *per* 24 h and creatinine level decreased to 350 mmol/L. Abdominal ultrasonography excluded hydronephrosis, perirenal or retroperitoneal collections. Anti-thymocyte globulin (ATG), methylprednisolone, mycophenolat mofetil and tacrolimus were used as immunosuppressive therapy. The patient was discharged on the 18th postoperative day after the uneventful postoperative period. On the discharge day 5 L of diuresis and creatinine 95 mmol/L were recorded. One year after the transplantation, kidney function was satisfied, with diuresis of 3 L *per* 24 h, creatinin level of 99 mmol/L and good perfusion of kidney and flow through anastomoses verified by color Doppler exam.

Discussion

The first case of anastomosis of the renal artery and the graft was described by Sterioff et al. ¹ in 1974 and repeated by Ahlmén et al. ². The authors did not notice any complications or technical difficulties in implementing the same ^{1,3}. The first simultaneous aortoiliac reconstruction and kidney transplantation was published by Cerili et al. ³ in 1977.

In modern transplant surgery it is necessary to extend criteria for renal transplantation because a large number of patients with ESRD on HD. Numerous comorbidities, including diabetes, hypertension, and severe atherosclerotic changes on all arterial vessels, contribute to increased risks for transplantation procedures.

A certain number of these patients, especially patients with aortoiliac segment atherosclerotic changes, require vascular procedures before or during kidney transplantation ⁴. Based on literature data 16.7% vascular grafts were lost in the first month after reconstruction ⁵. Surgical correction of aortoiliac pathology may be performed simultaneously with kidney transplantation with acceptable outcome in centers with experienced vascular surgeons ^{5,6}. If these procedures must be separated it is better to perform vascular reconstruction before transplantation. On the other side, based on their results, some authors suggest separate procedures approach,

as simultaneously preformed procedures are connected with higher risk of infection ⁷.

Matia et al. ⁸ suggest safe use of arterial allografts in the treatment of arterial occlusive disease or AAA simultaneously with renal transplantation. Moreover, endovascular stenting can be performed in the presence of extensive atherosclerosis before renal transplantation ⁹.

Numerous papers are dealing with a reconstruction works of AAA and aortoiliac segment after kidney transplantation. One of the problems is a prolonged cold ischemia time, which may jeopardize the renal transplant during simultaneous procedures.

Adequate pretransplant examination and preparation is vital for the successful performance of complicated vascular procedures after kidney transplantation ¹⁰⁻¹³. The key question is whether vascular reconstructive intervention should be done preoperatively or simultaneously with renal transplantations. It is suggested that renal transplant should be performed at least 6-8 weeks after vascular intervention ^{10,11}.

With wider inclusion criteria for renal transplants, MSCT angiography is a routine diagnostic method in pre-transplantation period, recommended in the Guidelines on Renal Transplantation from the European Association of Urology for peripheral artery disease, and cerebral occlusive vascular disease ¹⁴.

There are several surgical techniques in renal transplantation. The most frequently used technique is renal anastomosis with external iliac artery. In some cases, anastomosis with hypogastric artery is performed. Authors of this article prefer this type of anastomosis because of good results in long period ¹⁵. Several cases of hypogastric artery endarterectomy were performed in renal transplant patients during 17 years experience of renal transplantation in our hospital. In certain cases, CT scan interpretation was misleading and resulted in renal transplantation performance in severely changed atherosclerotic vessels. Advantages of the technique using anastomosis with the hypogastric artery are better positioning of the organ in the iliac bed and a low incidence of stenosis in anastomosis. The later, can be

explained by the similar diameter of hypogastric and renal artery¹⁵. The main disadvantage is wider dissection of the pelvis due to the position of hypogastric arteries.

After this successful case of aortobifemoral reconstruction and renal transplantation, we changed the protocol for renal transplant patients with inclusion of recipients with severe atherosclerotic disease. From that period, aortobifemoral bypass was performed in three pretransplant patients and they were on the waiting list.

Based on literature search, papers are mostly concentrated on aneurysm surgery after renal transplantation and a small amount of data are presented for reconstruction before renal transplantation. There is no consensus on the size of the aortic aneurysm that should be treated before transplantation. Based on our experience, all patients with AAA were rejected for renal transplant, and so far this is the first case of this reconstruction. Although AAA size of 4 cm is not an indication for aortic reconstruction, it needs to be solved as it presents contraindication for organ transplantation. Hypothetically, if aneurysm reaches diameter necessary for the reconstruction, renal transplantation will be technically difficult to perform with a high perioperative risk.

Occlusions of the iliac arteries are a strong contraindication for renal transplantation. Different degrees of iliac arteries stenosis represent a relative contraindication. Abdominal aneurysm

and iliac artery stenosis in this patient did not require reconstruction *per se*, but as preparation for renal transplantation aortobifemoral reconstruction was absolutely indicated.

Conclusion

Vascular reconstruction of the aortoiliac segment with synthetic graft is the first step in preparation patients for renal transplantation. Use of synthetic graft is not contraindication for kidney transplantation. Patients with extended indications, including those with severe atherosclerosis are accepted on the waiting list.

Adequate preparation of patients with extended criteria for transplantation with severe aortoiliac disease will improve results of renal transplantation and consequently, decrease the number of patients on HD. However, multicentric studies and prolonged "follow-ups" in the posttransplantation period are needed for a definitive conclusion.

Competing interests

The authors declare that this study was not financially supported by any funds and that there are no conflicts of interests regarding the content of this article

R E F E R E N C E S

1. Sterioff S, Zachary JB, Williams GM. Dacron vascular grafts in renal transplant patients. *Am J Surg* 1974; 127(5): 525–8.
2. Ahlmén J, Henriksson C, Claes G, Gelin LE, Thorén O. Successful kidney transplantation in a man with Dacron "trouser" prosthesis. *Scand J Urol Nephrol* 1979; 13(1): 133–5.
3. Cerilli J, Evans WE, Vaccaro PS. Successful simultaneous renal transplantation and abdominal aortic aneurysmectomy. *Arch Surg* 1977; 112(10): 1218–9.
4. Galazka Z, Grochowicki T, Jakimowicz T, Kowalczyński M, Szmidt J. Is severe atherosclerosis in the aortoiliac region a contraindication for kidney transplantation. *Transplant Proc* 2011; 43(8): 2908–10.
5. Tsvian M, Neri F, Nardo B, Bertelli R, Cavallari G, Fuga G, et al. Aortoiliac surgery concomitant with kidney transplantation: a single center experience. *Clin Transplant* 2009; 23(2): 164–7.
6. Pittaluga P, Hassen-Khodja R, Cassuto-Viguier E, Batt M, Declémy S, Bariseel H, et al. Aortoiliac reconstruction and kidney transplantation: A multicenter study. *Ann Vasc Surg* 1998; 12(6): 529–36.
7. Gony P, Lenot B, Decaix B, Rondeau E, Kitzis M, Lacave R, et al. Aortoiliac surgery and kidney transplantation. *Ann Vasc Surg* 1991; 5(1): 26–31.
8. Matia I, Adamec M, Varga M, Janousek L, Lipar K, Viklicky O. Aortoiliac reconstruction with allograft and kidney transplantation as a one-stage procedure: Long term results. *Eur J Vasc Endovasc Surg* 2008; 35(3): 353–7.
9. Abou-Jaoudé MM, Beteddini OS, Khalaf AN. Chronic Renal Failure and Aortoiliac Disease: Two Cases with Different Treatments and Outcome, and Literature Update. *J Transplant Technol Res* 2013; 3(1): 120.
10. Gibbons GW, Madras PN, Wheelock FC, Sahyoun AL, Monaco AP. Aortoiliac reconstruction following renal transplantation. *Surgery* 1982; 91(4): 435–7.
11. Hughes JD, Milfeld DJ, Shield CF. Renal transplant perfusion during aortoiliac aneurysmectomy. *J Vasc Surg* 1985; 2(4): 600–2.
12. Lacombe M. Abdominal aortic aneurysmectomy in renal transplant patients. *Ann Surg* 1986; 203(1): 62–8.
13. Harris JP, May J. Successful aortic surgery after renal transplantation without protection of the transplanted kidney. *J Vasc Surg* 1987; 5(3): 457–61.
14. Heidenreich A, Aus G, Bolla M, Joniau S, Matveev VB, Schmid HP, et al. Guidelines on prostate cancer. *Eur Urol* 2007. Available from: <http://www.uroweb.org/professional-resources/guidelines/>
15. Tomić A, Milović N, Marjanović I, Bjelanović Z, Leković I, Micković S, et al. Different techniques of vessel reconstruction during kidney transplantation. *Vojnosanit Pregl* 2015; 72(7): 614–8.

Received on June 9, 2014.

Revised on June 3, 2015.

Accepted on August 27, 2015.

Online First June, 2016.